

Right Ventricular Infarction

Taletha Carter, RN, MS, CCRN
Keith Ellis, MD

Right ventricular infarction (RVI) was initially described approximately 70 years ago. However, it was not until 1974 when Cohn et al¹ published the results of their landmark study and described the clinical and hemodynamic features of RVI that this abnormality was recognized as a distinct clinical entity. Cohn et al reported that the delay in recognizing RVI was due to the notion

that the right ventricle was not a necessary component of the circulation. This idea was fueled by experiments in dogs that showed that when the right ventricle was excluded, no change in venous pressure or cardiac output occurred.²⁻⁴ Successful surgical procedures that bypassed the right ventricle were being used at the time to treat cyanotic congenital heart disease, further supporting the “lack of importance” of the right ventricle.^{2,5} After the publication of Cohn et al in 1974, a new era of investigation on RVI began, which disproved many previously held ideas.

RVIs accompany extensive inferior-posterior myocardial infarctions. The occurrence of an inferior left ventricular infarction involving the right ventricle ranges from 14% to 84%, but is typically thought to be about 50%.^{2,6,7} In autopsy series,^{2,7} approximately 13% of hearts with an anterior wall myocardial infarction also had evidence of RVI. In autopsy studies in which a myocardial infarction was detected, isolated RVI was detected in less than 3% of the specimens examined.^{2,7} Chronic lung disease and right ventricular hypertrophy are considered significant risk factors for RVI.^{6,7}

The signs and symptoms of RVI are similar to those of left ventricular infarction. Less than 50% of patients have hemodynamic compromise. RVI is difficult to diagnose because the prognosis is determined largely by the extent of left ventricular involvement.⁶ The right ventricle recovers much of its function during the months after the myocardial infarction, usually returning to its baseline level of function.⁸⁻¹⁰ Patients with minimal involvement of the left ventricle have an excellent long-term prognosis.

Early recognition of RVI is critical for reducing mortality and complications associated with this cardiac injury. Inferior myocardial infarction with RVI has a high mortality rate of 25% to 30% as compared with only 6% for inferior infarctions not involving the right ventricle.¹¹ Volume resuscitation and reperfusion therapy should be started early.^{9,12-14} In this article, we discuss the pathophysiology, clinical features, diagnosis, treatment, and complications associated with RVI.

Pathophysiology

The hemodynamic consequences of RVI are unique. An appreciation of the important differences between RVI and left ventricular infarction requires a review of the function of the right ventricle and its blood supply.

Although the right and left ventricles differ markedly in size and energy consumption, their cardiac output is equivalent. The right ventricle functions with about one sixth the muscle mass and performs one



To receive CE credit for this article, visit the American Association of Critical-Care Nurses' (AACN) Web site at <http://www.aacn.org>, click on “Education” and select “Continuing Education,” or call AACN's Fax on Demand at (800) 222-6329 and request item No. 1111.

Authors

Taletha Carter is a clinical nurse specialist in the cardiac step-down units at the Cleveland Clinic Foundation, Cleveland, Ohio. She has 15 years of experience in nursing, with a concentration in critical care.

Keith Ellis completed his cardiology fellowship at the Cleveland Clinic Foundation, Cleveland, Ohio. He completed his interventional cardiology fellowship at the University of Texas Health Sciences Center in Houston and is affiliated with Diagnostic Cardiology of Houston.

To purchase reprints, contact The InnoVision Group, 101 Columbia, Aliso Viejo, CA 92656. Phone, (800) 809-2273 or (949) 362-2050 (ext 532); fax, (949) 362-2049; e-mail, reprints@aacn.org.

Case Report

A 70-year-old man came to the emergency department after experiencing chest pain and shortness of breath for approximately 4 hours. He described his chest pain as 6 on a scale of 1 to 10 on which 10 indicates the most severe pain, and he stated that he could not catch his breath. His medical history included myocardial infarction, diabetes, hyperlipidemia, and percutaneous transluminal coronary angioplasty of the left anterior descending artery 3 years ago. Other cardiac risk factors included use of tobacco. His vital signs were heart rate 90/min, blood pressure 108/70 mm Hg, and respirations 22/min. He was alert and oriented to person, place, and time. He had increased jugular venous distention, his lungs were clear on auscultation, and his heart sounds were regular with no murmurs, rubs, or gallops. His abdomen was soft, and his extremities had no edema.

Initial laboratory values included a troponin T level of 0.24 µg/L and normal levels of creatine kinase and creatine kinase-MB. The hemoglobin level was 13.2 g/dL, the platelet count was $232 \times 10^9/L$, and the creatinine level was 80 µmol/L (0.9 mg/dL). The initial electrocardiogram (ECG) showed ST-segment elevation in leads II, III, and aVF.

The patient was given 3 L of oxygen by nasal cannula. Administration of intravenous nitroglycerin was started at a rate of 10 µg/min. A bolus of 5000 U of heparin was injected intravenously, and then heparin was infused at a rate of 1000 U/h. Shortly thereafter the patient complained of being light-headed and “not feeling well.” His blood pressure was now 80/60 mm Hg, and his chest pain had intensified to 8 on a scale of 1 to 10. The intravenous nitroglycerin was discontinued because of hypotension, and a fluid bolus of 250 mL of isotonic sodium chloride solution was administered. The next ECG showed ST-segment elevation in inferior leads II, III, and aVF (Figure 1). A right ventricular myocardial infarction was suspected, and a right-sided ECG revealed

ST-segment elevation in the V₄R right precordial lead (Figure 2). The diagnosis was inferior wall myocardial infarction with right ventricular involvement. The patient was taken to the cardiac catheterization laboratory immediately, where left- and right-sided heart catheterization was performed. The catheterization revealed a proximal stenosis of the right coronary artery that was treated with angioplasty and stenting. The patient was monitored in the coronary intensive care unit for 2 days and then was transferred to a telemetry unit. He was discharged home on hospital day number 7 with the following medications: metoprolol (Lopressor), ramipril (Altace), aspirin, atorvastatin (Lipitor), and clopidogrel (Plavix).

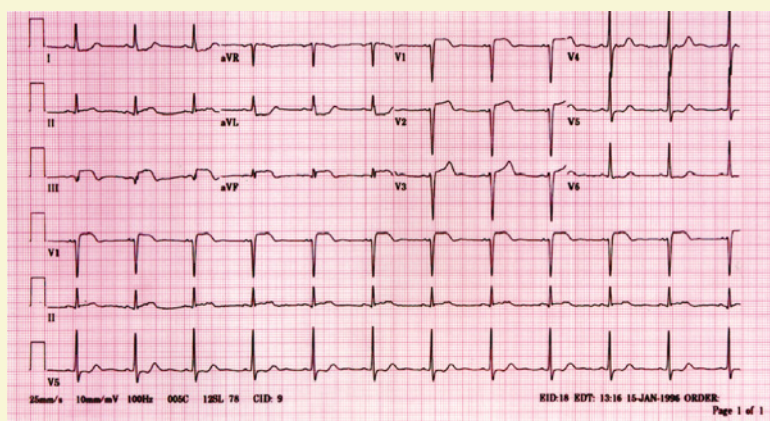


Figure 1 12-lead electrocardiogram shows ST-segment elevation in leads II, III, and aVF in a patient with an inferior wall myocardial infarction. Additional ST-segment elevation in leads V₁ to V₃ suggests right ventricular infarction.

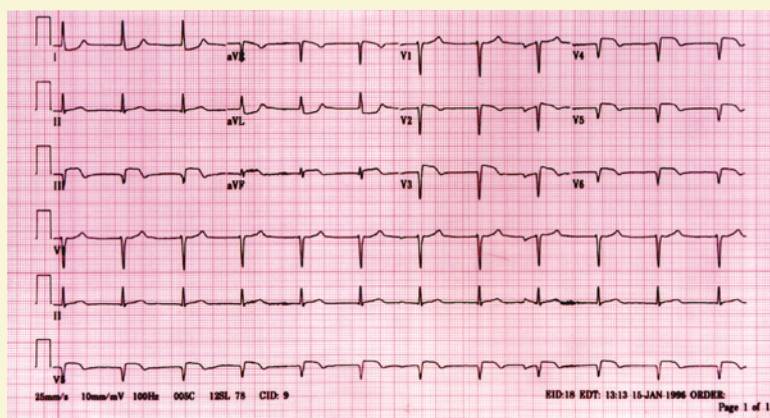


Figure 2 Right-sided electrocardiogram of the same patient as in Figure 1 shows ST-segment elevation and Q waves in lead V₄R.

fourth of the work of the left ventricle.^{7,9} The ability of the right ventricle to pump an equivalent cardiac output by using a quarter of the energy required by the left ventricle is due to the low resistance in pulmonary vasculature. The pulmonary vascular resistance is 10% of the systemic resistance, which is the resistance against which the left ventricle must pump.^{9,14} The right ventricle is a thin-walled structure with low oxygen demands, making extensive irreversible infarction unusual. Although transient ischemic dysfunction and stunning of the right ventricle occurs initially, recovery of function usually occurs over the long-term.^{11,15}

The coronary circulation (Figure 3) is made up of the left main trunk, which gives rise to the left anterior descending artery and the left circumflex artery. The right coronary artery also helps to make up the coronary circulation. The distribution pattern of the coronary arteries is right dominant in approximately 85% of the population. Dominance is defined by the artery that provides the posterior descending artery.¹⁴ Usually, the right coronary artery provides the posterior descending artery; in persons with this configuration, the system is considered right dominant. However, the left circumflex artery may provide the posterior descending artery; in persons with this configuration, 7.5% of the population, the system is considered left dominant.¹⁴ Last, the system is considered codominant if the circumflex and right coronary arteries provide the posterior descending artery; this situation occurs in 7.5% of the population.¹⁴

In right-dominant coronary circulation, the right ventricle receives its

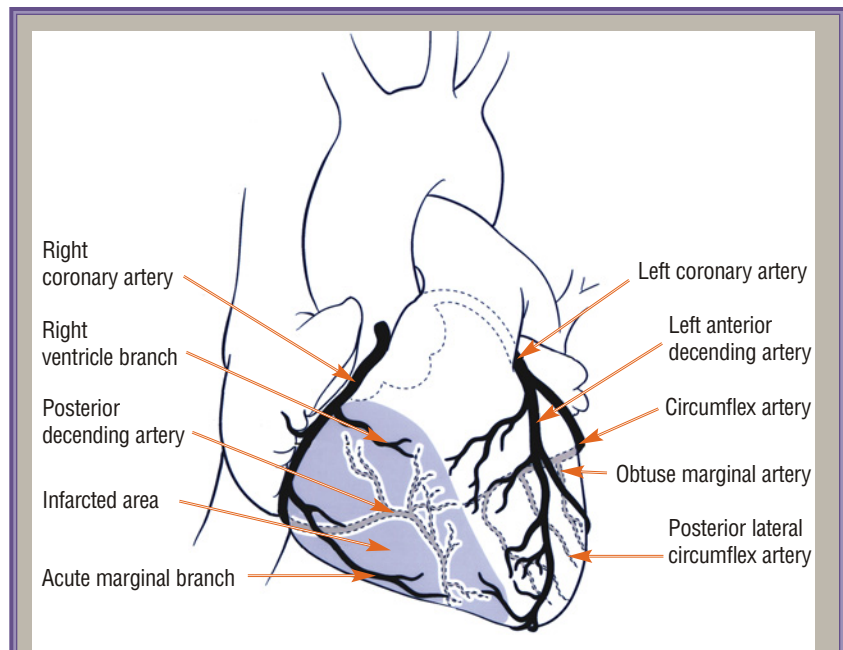


Figure 3 Coronary circulation.

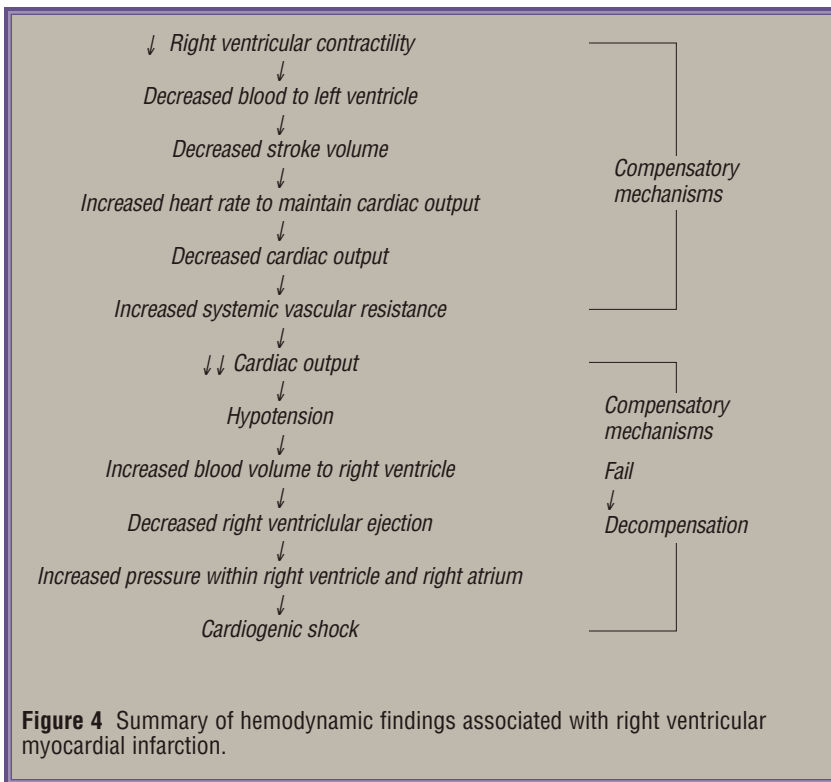
blood supply from acute marginal and right ventricular branches originating from the right coronary artery. In a left-dominant system, the right ventricle receives its blood supply from the circumflex artery. In codominant circulation, the right coronary artery and the left circumflex artery supply the right ventricle. Occasionally, the left anterior descending artery may supply parts of the right ventricle.

Unlike the left ventricle, the right ventricle receives its blood supply during systole and diastole via its rich network of collateral vessels. This physiological situation occurs because the right ventricle is a low-pressure chamber. The right ventricle is responsible for receiving systemic blood and pumping it to the pulmonary circulation, where the blood receives oxygen and nutrients. The blood is then received in the left side of the heart to be pumped systemically into the body by the left ventricle. The right ventricle functions as a thin-walled volume pump that is

sensitive to alterations in preload and afterload, especially when contractile function is impaired. Most often, an RVI occurs in concert with an inferior wall myocardial infarction caused by a proximal occlusion of the right coronary artery.^{7,14} However, RVIs may develop with the occlusion of any coronary artery.⁹

When an occlusion of the right coronary artery occurs, blood flow to the acute marginal and right ventricular branches, which supply the right ventricular free wall, is blocked. If occlusion occurs distal to these marginal branches, RVI does not occur.

In patients with coronary artery disease, right ventricular hypertrophy may be a predisposing factor for RVI.⁷ Once an infarction has occurred, contractility of the right ventricle is impaired, leading to decreased right ventricular compliance, decreased stroke volume, and, subsequently, decreased cardiac output (Figure 4). The ischemic right ventricle is unable to handle venous return. The inabil-



ity of the ischemic right ventricle to handle venous return results in a decrease in blood being pumped through the pulmonary system and therefore less oxygenated blood to be pumped out by the left ventricle. The infarcted area also becomes stiff and noncompliant as blood begins to pool in the failing right ventricle. The impaired contractility also leads to blood pooling in the right atrium, resulting in an increased central venous pressure and systemic venous pressure. Right ventricular dilatation, which results from impaired contractility and an increase in right ventricular diastolic pressure, causes a leftward shift of the interventricular septum toward the left ventricle. This shifting of the interventricular septum may result in an increase in left ventricular end-diastolic pressure.^{2,6,7} The increase in left ventricular end-diastolic pressure leads to decreased left ventricular compliance,

impaired left ventricular filling, decreased stroke volume, and, finally, a decrease in cardiac output. Initially, left ventricular function may remain relatively intact, resulting in the absence of pulmonary edema, with clear lungs on auscultation and normal findings on chest radiographs. However, as the infarction progresses, marked impairment in left ventricular contractile function and diastolic abnormalities may occur.^{2,16}

Initially, as cardiac output and blood pressure begin to decrease, heart rate increases in an effort to maintain cardiac output. The increase in heart rate shortens diastole or ventricular filling, and eventually a further decline in cardiac output and blood pressure may occur. Loss of the active right ventricular systolic pressure wave may result in further hemodynamic compromise. Enhanced atrial contractility is needed to overcome the increase in

myocardial stiffness associated with RVI. Therefore, use of nitrates and diuretics and the loss of atrioventricular synchrony (atrial fibrillation, atrial flutter, and complete heart block) may have profound adverse effects on hemodynamic status. In patients who require mechanical ventilation, addition of positive end-expiratory pressure will decrease preload. Preload is the primary stimulus for right ventricular contractility in patients with RVI. The loss of atrioventricular synchrony and conduction defects further decrease cardiac output by limiting ventricular filling and chronotropic response.^{2,6,7} Cardiogenic shock and death most likely will occur if preload and atrioventricular synchrony are not maintained. The mortality associated with cardiogenic shock due to RVI is equivalent to the mortality associated with cardiogenic shock due to left ventricular infarction; both have approximately 55% to 60% in-hospital mortality.¹⁷

Clinical Manifestations

The diagnosis of RVI should always be considered in patients who have an inferior wall myocardial infarction. Early diagnosis is critical to avoid therapy that may adversely affect the outcome of RVI.^{18,19} The presence of ST-segment elevation in leads II, III, and aVF on an ECG are always suggestive of RVI.^{20,21} A right-sided ECG should be obtained immediately. Normal placement of the precordial leads to the left of the sternum does not result in direct visualization of the right ventricle. When the precordial leads are placed to the right of the sternum, over the right ventricle, elevation in the ST

segment in lead V₄R is highly suggestive of RVI. The classic combination of elevated jugular venous pressure, hypotension, and clear lung fields also suggests RVI.^{2,6,20,22} However, pericardial tamponade, constrictive pericarditis, and pulmonary embolus may share some of these features and must be excluded.

Echocardiography and hemodynamic monitoring with a pulmonary artery catheter are helpful in distinguishing pericardial tamponade and pulmonary embolus. Compared with pericardial tamponade, pulmonary embolus is associated with higher right ventricular pressures, pulmonary artery pressures, pulmonary vascular resistance, and hypoxemia. Therefore, an estimation of right-side pressures and a detailed history and physical examination are helpful. The Kussmaul sign, an inspiratory increase in jugular venous pressure, has been described in patients with RVI.¹⁶ Pulsus paradoxus, an inspiratory decrease in systolic blood pressure of more than 10 mm Hg, has also been described.

If RVI is left untreated, cardiac output may decrease, and signs of hypoperfusion may develop, including delayed capillary filling, cool clammy skin, hypotension, changes in mental status, and decreased urine output.² Right ventricular gallop, tricuspid regurgitation, and atrioventricular dissociation manifested as cannon a waves in the jugular venous pulse are other physical findings associated with RVI (see Table). Hemodynamic parameters reflect increased pressures on the right side of the heart. Patients with intact atrial perfusion may experience augmented atrial contraction resulting in enhanced a and x descent wave-

forms but diminished y descent in the jugular venous pulsation.¹⁶ Patients with depressed right atrial function have higher right atrial and systemic venous pressure but depressed a wave, x descent, and y descent. Cardiac output and cardiac index are decreased.¹⁶

Pulmonary artery occlusion pressure, also known as pulmonary capillary wedge pressure, may be normal or decreased. An increased pulmonary capillary wedge pressure is indicative of left ventricular dysfunction and may occur as a result of decreased left ventricular compliance or concomitant left ventricular ischemia or infarction. The lungs may have crackles as a result of pulmonary congestion associated with left ventricular dysfunction. Patients may also experience an increase in pulmonary artery pressures, which occur as a result of left ventricular dysfunction. As cardiac output further decreases, systemic vascular resistance increases, further compromising left ventricular function.

Dysrhythmias such as bradycardia, high-degree atrioventricular block, and atrial fibrillation are associated with approximately 50% of RVIs.¹⁶ Complete heart block is common in RVI. Atrial fibrillation may also occur as a result of atrial infarction and elevation of left atrial pressure. The loss of atrioventricular synchrony in complete heart block and atrial fibrillation may further contribute to a decline in cardiac output. Dysrhythmias should be treated promptly to reduce morbidity and mortality.

Diagnosis

Several invasive and noninvasive studies are available to assist in the

Clinical manifestations of right ventricular infarction

- Increased jugular venous pressure
- Hypotension
- Clear lung fields
- Kussmaul sign
- Pulsus paradoxus
- Cool, clammy skin
- Decreased capillary filling
- Change in mental status
- Decreased urine output
- High-degree atrioventricular heart block
- Ventricular gallop
- Tricuspid regurgitation

rapid and accurate diagnosis of RVI. These include ECG, chest radiography, hemodynamic monitoring, echocardiography, and nuclear imaging.^{18,23}

Electrocardiography

Electrocardiography is rapid, noninvasive, and readily available. For a right-sided ECG, the precordial leads are placed across the right side of the chest in a mirror image to their placement on the left side (Figures 5 and 6). A 1-mm elevation in the ST segment in lead V₄R is 70% sensitive and 100% specific for RVI.^{20,22} ST-segment elevation in lead V₄R is a strong independent predictor of major complications and in-hospital mortality in patients with RVI. However, elevation of the ST-segment in this lead is transient and may resolve within 10 to 12 hours of the onset of signs and symptoms of RVI.²² Therefore, right-sided ECG should be done as quickly as possible. Other ECG findings may include ST-segment elevation in leads V₁ to V₄ (can be confused with anteroseptal infarction) or greater ST-segment elevation in lead III than in lead II in inferior infarction.²⁴ Right bundle branch block and complete heart

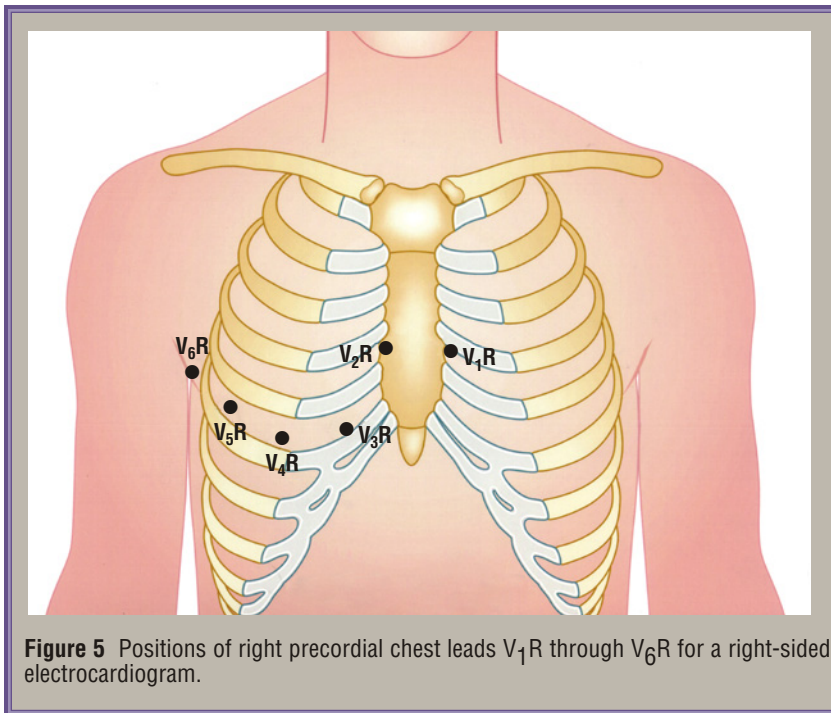


Figure 5 Positions of right precordial chest leads V₁R through V₆R for a right-sided electrocardiogram.

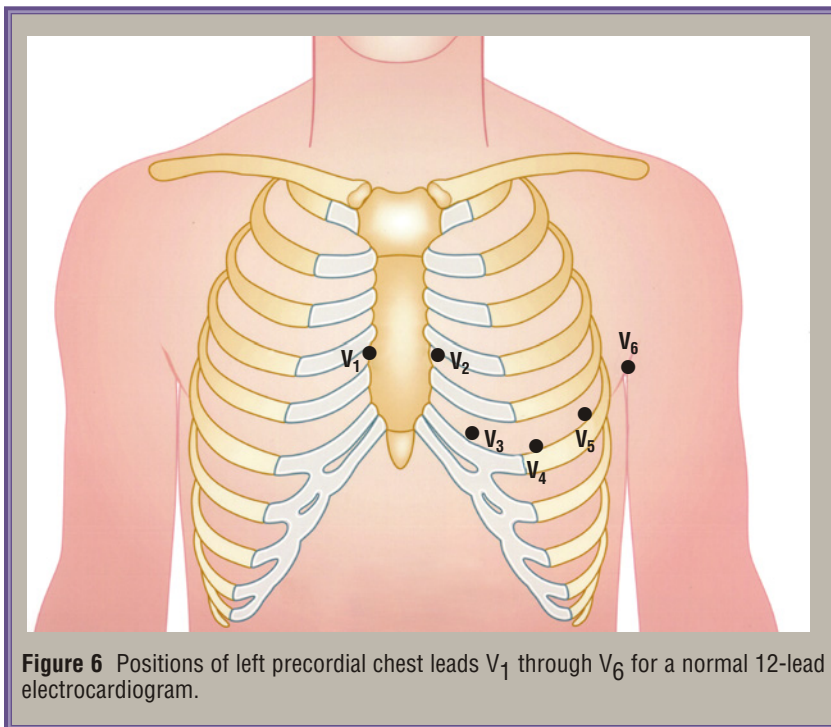


Figure 6 Positions of left precordial chest leads V₁ through V₆ for a normal 12-lead electrocardiogram.

block are the most common conduction disturbances associated with RVI. ECGs should be obtained as early as possible and are critical for an accurate diagnosis and initiation of treatment.

Chest Radiography

Chest radiography is not particularly helpful in making the diagnosis of RVI. Early on the lung fields are usually clear, and radiographs may indicate atrial enlargement or ven-

tricular enlargement as a result of the infarction. Chest radiography is important for determining the presence of pulmonary edema.

Hemodynamic Monitoring

Insertion of a pulmonary artery catheter is a relatively rapid invasive procedure that can provide minute-to-minute information on intracardiac pressures and cardiac output. Hemodynamic monitoring is helpful in distinguishing other conditions that may mimic RVI. The diagnosis of RVI can be confirmed when the right atrial pressure exceeds 10 mm Hg and the ratio of the right atrial pressure to pulmonary capillary wedge pressure exceeds 0.8; normal is less than 0.6.¹⁶ In earlier studies, a prominent y descent in the right atrial waveform was considered the hallmark of RVI. These results were related to ECG criteria and were obscured by atrioventricular dyssynchrony. Further studies relating right atrial waveforms to right ventricular mechanics indicated that a predominant x descent was associated with RVI¹⁶ (Figure 7). However, the relationship of the x and y descents is dependent on atrial function.

Echocardiography

Echocardiography provides quantitative information about right and left ventricular function. This procedure is performed quickly in an intensive care unit at the bedside and provides an immense amount of information. Echocardiograms show abnormalities in wall motion as well as changes in the dimensions of the right ventricle and the atria, which may occur in RVI (Figure 8). Echocardiography is used to estimate right ventricular systolic pres-

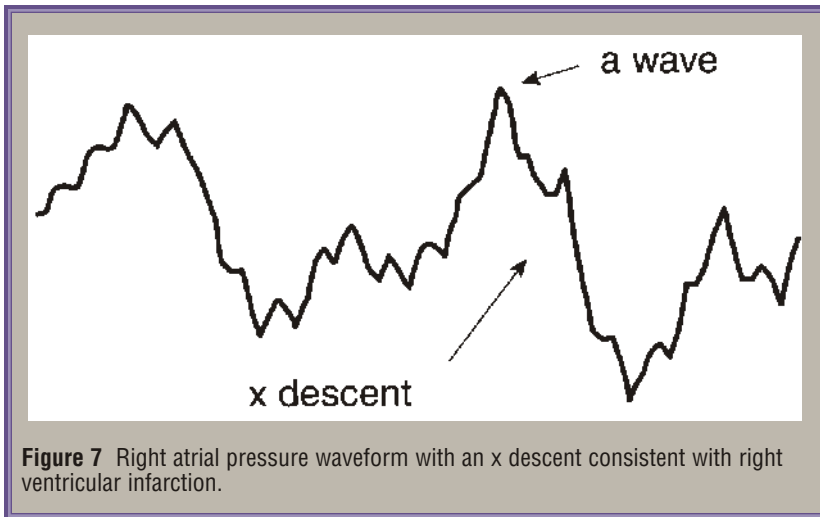


Figure 7 Right atrial pressure waveform with an x descent consistent with right ventricular infarction.

sure, which may help in diagnosing pulmonary hypertension.

Complications of infarctions such as a patent foramen ovale, ventricular septal defect, and worsening of valvular regurgitation may also be detected on echocardiograms. Patent foramen ovale tends to develop as the right atrial pressure increases, resulting in right-to-left shunting. The short-axis view is used to detect hemodynamically significant RVI. The highest sensitivity of this view is 82%; the specificity ranges from 62% to 93%.^{7,12} Bowing of the interatrial septum toward the left atrium indicative of an increased gradient in pressure from the right atrium to the left atrium is an important prognostic marker for RVI.

Nuclear Imaging

Nuclear imaging is not very useful early on in the diagnosis of an RVI. It is more beneficial after primary therapy and helps determine ventricular function and perfusion. Radionuclide angiography has a sensitivity of 92% and a specificity of 82% for the detection of hemodynamically significant RVI.⁷ Technetium pyrophosphate scintigraphy has a much lower

sensitivity and specificity for detecting RVI. Nuclear imaging is most useful as a prognostic tool.

Nursing Management

All patients with signs and symptoms of myocardial infarction should have 12-lead ECG. A simple mnemonic to guide nursing care in patients with RVI is *RRVVII*, empha-

sizing reperfusion, rhythm, vital signs, volume, inotropes, and intra-aortic balloon pump. In addition, right-sided ECGs should be obtained in all patients who have changes in the inferior wall. When right-sided ECGs are obtained, the right-sided leads must be clearly labeled so no confusion with the normal 12-lead ECG occurs. In patients with RVI, ST-segment elevation in lead V₄R returns to baseline within 10 to 12 hours after signs and symptoms begin; therefore, a right-sided ECG should be obtained as quickly as possible.

Patients with RVI are given oxygen therapy and are monitored continuously for dysrhythmias. Bradycardia, high-degree atrioventricular block and atrial fibrillation may occur in RVI. Loss of atrioventricular synchrony in heart block and atrial fibrillation results in a further reduction in cardiac output, predisposing patients to cardiogenic shock. A

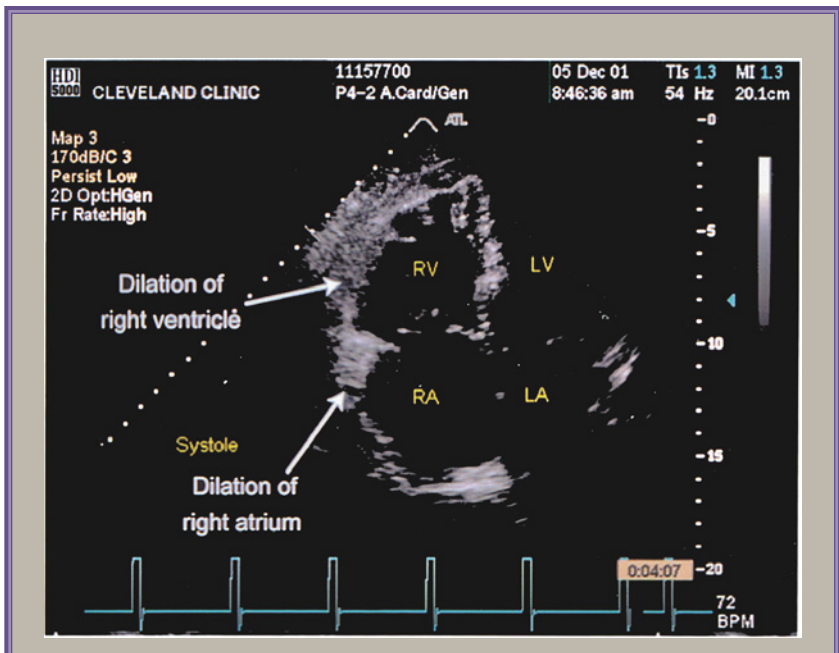


Figure 8 Echocardiogram shows dilatation of the walls of the right atrium and right ventricle consistent with right ventricular infarction.

transvenous pacemaker may be indicated. Atrial fibrillation can be managed by using immediate cardioversion to reverse signs and symptoms of cardiogenic shock.

Nitroglycerin is generally indicated in myocardial infarction because of the drug's vasodilatory effects on blood vessels, which lead to decreased ischemia, decreased myocardial oxygen consumption, and, subsequently, an improvement in blood flow to the myocardium. However, vasodilators, diuretics, and morphine are not well tolerated by patients with RVI and may lead to severe hypotension. The effects of these medications may cause a reduction in preload by decreasing filling pressures and subsequently decreasing cardiac output. Therefore, volume loading with an isotonic solution such as isotonic sodium chloride solution is recommended as the initial therapy in RVI. Progressive volume loading can produce an incremental increase in right-sided filling pressures, systolic blood pressure, and cardiac output.^{1,25} Fluid volume loading is based on Starling's law, which states that the greater the amount of stretch of the ventricle, the more forceful is the contraction.²³ Insertion of a pulmonary artery catheter may be indicated for monitoring hemodynamic changes. In RVI, right atrial pressure, measured as central venous pressure, is increased more than 10 mm Hg (normal 2-6 mm Hg), and cardiac output (normal 4-8 L/min) and cardiac index (normal 2-4; calculated as cardiac output in liters per minute divided by body surface area in square meters) are decreased. Pulmonary capillary wedge pressure may be normal or decreased (normal 8-12 mm Hg) depending on whether

left ventricular involvement occurs. Pulmonary capillary wedge pressure is increased in patients with left ventricular failure.

The response to volume loading in patients with RVI varies. If the hemodynamic parameters do not change markedly after volume loading with intravenous fluids, addition of an inotropic medication, such as dobutamine (Dobutrex), may be needed to enhance ventricular contractility and cardiac output. Dobutamine may be effective if volume loading is unsuccessful.^{7,12} The dosage is adjusted to maintain an adequate cardiac output. The right ventricle is particularly sensitive to β -adrenergic stimulation or beta-blockade during ischemic conditions. This sensitivity accounts for the effectiveness of dobutamine in this situation and the rapid decline in cardiac output and clinical status that may occur in patients given β -blockers. In patients with acute right ventricular infarctions, treatment with aspirin, clopidogrel, intravenous heparin (Lovenox), and glycoprotein IIa/IIIb inhibitors should be considered.

If indicated, early reperfusion therapy can be beneficial. The earlier reperfusion occurs, the better is the chance of decreasing the size of the infarct. Urgent reperfusion can involve administration of fibrinolytic agents or percutaneous coronary intervention. Compared with patients not treated with early perfusion, patients given this treatment have more preservation of ventricular function and rapid hemodynamic improvement.¹³

When substantial left ventricular dysfunction occurs in conjunction with an RVI, treatment goals become somewhat more focused on decreasing afterload to prevent further decrease in cardiac output and

shock. In patients who are not hypotensive, cautious use of nitroglycerin and nitroprusside may help reduce afterload and improve cardiac output. Finally, if cardiac output continues to decrease and shock is eminent, an intra-aortic balloon pump can be used to reduce afterload and provide the added benefit of augmenting coronary perfusion. Coronary angiography should be performed in this situation if it was not performed earlier.

Complications

After RVI, mechanical and/or electrical complications may develop. Papillary muscle dysfunction or rupture may occur, resulting in marked worsening of mitral or tricuspid regurgitation. As right atrial pressure increases, right-to-left shunting may develop through a patent foramen ovale. Ventricular septal defects may also develop as a result of RVI. Patients with RVI require monitoring and echocardiography to detect the development of these complications.

Bradycardia and complete heart block may also occur as a result of RVI. These may be due to the Bezold-Jarisch reflex or to infarcted conduction tissue. The Bezold-Jarisch reflex results in bradycardia and hypotension due to stimulation of receptors heavily concentrated in the inferior and posterior walls of the heart. This reflex is due to the stimulation of afferent and efferent limbs of the vagus nerves, which leads to enhanced parasympathetic tone. The vagus nerve is close to the inferior aspect of the heart, a situation that results in augmented activation in association with inferior myocardial infarctions. Telemetric monitor-

ing is necessary, and further treatment with atropine or temporary pacemaker may be required.

Conclusion

The diagnosis of RVI can be challenging. Although patients with RVI have clinical features similar to those of patients with left ventricular infarction, the hemodynamic consequences of the 2 infarctions are vastly different. ECG can be helpful in making the correct diagnosis. RVI should be considered in all patients who have an inferior myocardial infarction. Use of right-sided ECG, echocardiography, and invasive hemodynamic monitoring can also be helpful in diagnosing RVI. Early detection, along with hemodynamic support, rapid reperfusion therapy, and knowledge of the potential complications, can help improve the outcome of patients with RVI.

Acknowledgments

We thank Deborah Klein, RN, MSN, CCRN, CS, for her editorial support, Leslie Rivers for secretarial support, John Passmore, MD, for advice and assistance, and the art and photography department at the Cleveland Clinic Foundation for assistance with the images.

References

1. Cohn JN, Guiha NH, Broder MI, Limas CJ. Right ventricular infarction: clinical and hemodynamic features. *Am J Cardiol.* 1974;33:209-214.
2. Setaro JF, Cabin HS. Right ventricular infarction. *Cardiol Clin.* 1992;10:69-90.
3. Kagan A. Dynamic responses of the right ventricle following extensive damage by cauterization. *Circulation.* 1952;5:816-823.
4. Starr I, Jeffers WA, Meade RH. The absence of conspicuous increments of venous pressure after severe damage to the right ventricle of the dog, with a discussion of the relation between clinical congestive heart failure and heart disease. *Am Heart J.* 1943;26:291.
5. Sade RM, Casteneda AR. The dispensable right ventricle. *Surgery.* 1975;77:624-631.
6. Goldstein JA. Right heart ischemia: pathophysiology, natural history, and clinical management. *Prog Cardiovasc Dis.* 1998;40:325-341.
7. Kinch JW, Ryan TJ. Right ventricular infarction. *N Engl J Med.* 1994;330:1211-1217.
8. Andersen HR, Falk E, Nielson D. Right ventricular infarction: frequency, size and

topography in coronary heart disease: a prospective study comprising 107 consecutive autopsies from a coronary care unit. *J Am Coll Cardiol.* 1987;10:1223-1232.

9. Ratliff NB, Hackel DB. Combined right and left ventricular infarction: pathogenesis and clinicopathologic correlations. *Am J Cardiol.* 1980;45:217-221.
10. Ketikoglou DG, Karvounis HI, Papadopoulos CE, et al. Echocardiographic evaluation of spontaneous recovery of right ventricular systolic and diastolic function in patients with acute right ventricular infarction associated with posterior wall left ventricular infarction. *Am J Cardiol.* 2004;93:911-913.
11. Zehender M, Kasper W, Kauder E, et al. Right ventricular infarction is an independent predictor of prognosis after acute inferior myocardial infarction. *N Engl J Med.* 1993;328:981-988.
12. Haji SA, Movahed A. Right ventricular infarction: diagnosis and treatment. *Clin Cardiol.* 2000;23:473-482.
13. Sakabe K, Nakamura M, Kitagawa Y, et al. Primary angioplasty for isolated right ventricular infarction. *Catheter Cardiovasc Interv.* 2001;53:248-252.
14. Hochman JS, Gersh BJ. Acute myocardial infarctions. In: Topol EJ, Califf RM, Isner JM, et al, eds. *Textbook of Cardiovascular Medicine.* 2nd ed. Philadelphia, Pa: Lippincott-Williams & Wilkins; 2002: 421-462.
15. Horan LG, Flowers NC. Right ventricular infarction: specific requirements of management. *Am Fam Physician.* 1999;60:1727-1734.
16. Mittal SR, Garg S, Lalgaria M. Jugular venous pressure and pulse wave form in the diagnosis of right ventricular infarction. *Int J Cardiol.* 1996;53:253-256.
17. Jacobs AK, Leopold JA, Bates E. Cardiogenic shock caused by right ventricular infarction. *J Am Coll Cardiol.* 2003;41:1273-1279.
18. Lanza M. Right ventricular infarction: when the power fails. *Dimens Crit Care Nurs.* 2002;21:122-126.
19. Levin TN, Samana F, Follman D, et al. Right ventricular MI: when to suspect, what to do. *J Crit Ill.* 1995;10:14-24.
20. Madias JE, Mahjoub M, Wijetilaka R. Standard 12-lead ECG versus special chest leads in the diagnosis of right ventricular infarction. *Am J Emerg Med.* 1997;15:89-90.
21. Stewart S, Kucia A, Poropat S. Early detection and management of right ventricular infarction: the role of the critical care nurse. *Dimens Crit Care Nurs.* 1995;14:282-291.
22. Fijewski TR, Pollack ML, Chan TC, Brady WJ. Electrocardiographic manifestations: right ventricular infarction. *J Emerg Med.* 2002;22:189-194.
23. Yager M. Right ventricular infarction in the emergency department: a review of pathophysiology, assessment, diagnosis, treatment and nursing care. *J Emerg Nurs.* 1996;22:288-292.
24. Hurst JW. Comments about the electrocardiographic signs of right ventricular infarction. *Clin Cardiol.* 1998;21:289.
25. Guiha NH, Limas CJ, Cohn JN. Predominant right ventricular dysfunction after right ventricular destruction in the dog. *Am J Cardiol.* 1974;33:254-258.